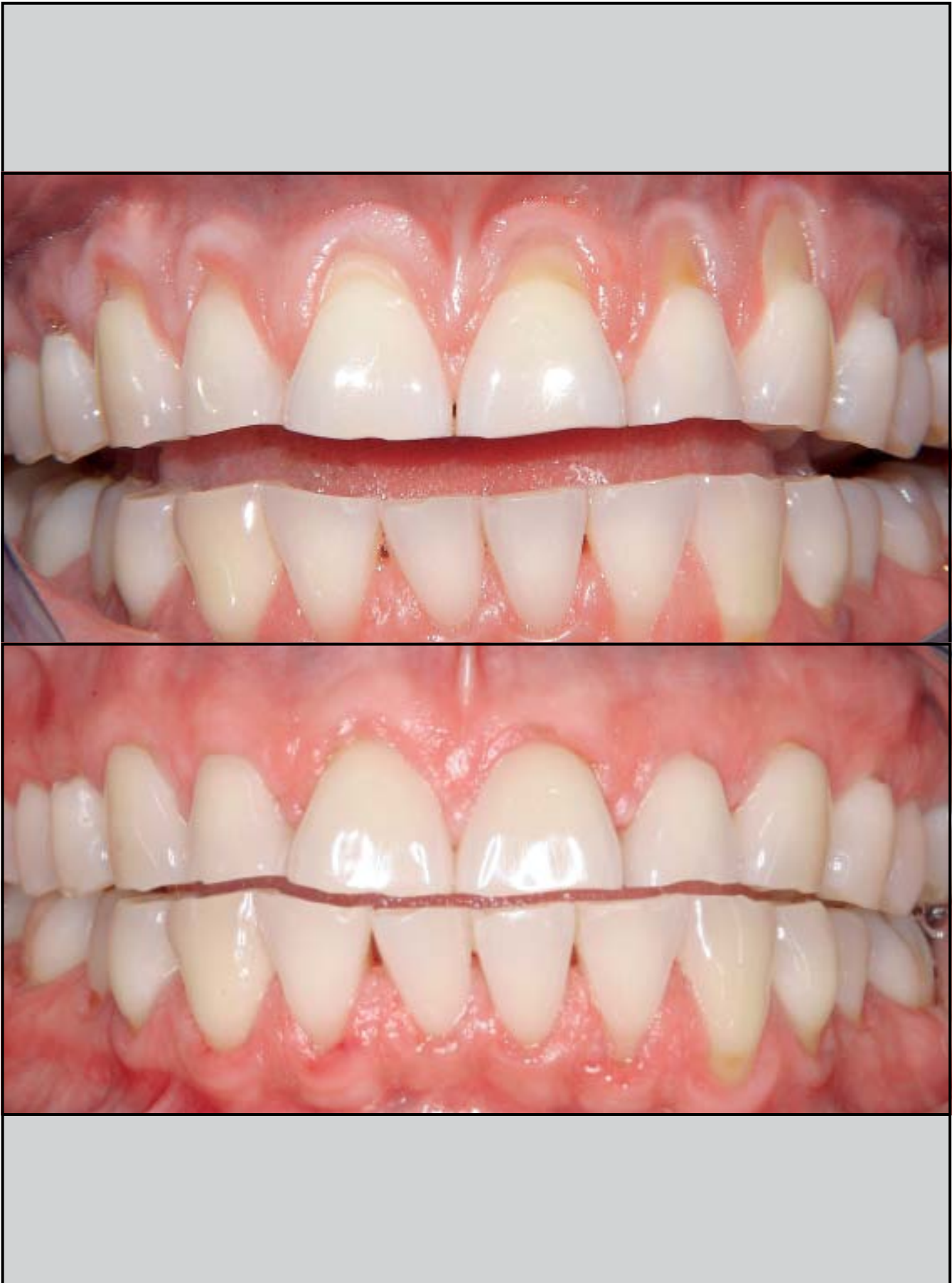
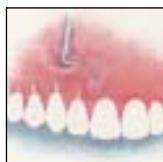


A Novel Approach to Root Coverage: The Pinhole Surgical Technique



John C. Chao, DDS*

Free connective tissue graft techniques are currently considered the most predictable surgical method for root coverage. However, morbidity associated with secondary graft sites has generated interest in other methods. The purpose of this study was to investigate the feasibility of a novel surgical approach to root coverage: the pinhole surgical technique (PST). This retrospective study examined the results of PST used for 43 consecutive patients on 121 recession sites, of which 85 were Class I or II and 36 were Class III. Mean initial recession for all sites was 3.4 ± 1.0 mm. The mean assessment period was 18 ± 6.7 months. No secondary surgical site was necessary, and only bioresorbable membrane or acellular dermal matrix was used as graft material. PST required no releasing incision, sharp dissection, or suturing (when a bioresorbable membrane was used). Only one incision of 2 to 3 mm (for entry) was necessary for the entire procedure. Predictability of PST for Class I and II sites, measured as frequency of complete root coverage, was 81.2%. Effectiveness of PST for Class I and II sites, measured as mean percent defect reduction, was $94.0\% \pm 14.8\%$. When data from Class I, II, and III sites were combined, predictability and effectiveness were 69.4% and $88.4\% \pm 19.8\%$, respectively. The mean duration per procedure was 22.3 ± 10.1 minutes. The mean level of patient subjective esthetic satisfaction was 95.1% and was realized within a mean 7.34 ± 13.5 days. Postoperative complications were minimal. These results indicate that PST holds promise as a minimally invasive, predictable, effective, and time- and cost-effective method for obtaining optimal patient-based outcomes. (Int J Periodontics Restorative Dent 2012;32:521–531.)

*Private Practice, Alhambra, California.

Correspondence to: Dr John C. Chao, 100 S First Street, Alhambra, CA 91801;
fax: 626-284-8584; email: johnchaodds@sbcglobal.net.

The reestablishment of a stable periodontium concomitant with an optimal patient-centered outcome is said to be the objective of periodontal reconstructive surgery.¹⁻³ To meet this objective, various reconstructive surgical techniques for root coverage have been developed and reported over the years.⁴⁻¹² Currently, free connective tissue graft (FCTG) techniques are considered the gold standard and the most predictable approach for complete root coverage. However, FCTG techniques are associated with donor site complications such as postoperative pain, bleeding, and swelling.¹³ An in-depth analysis of FCTG and other current techniques led to the observation that all of these methods require a coronal approach for the entry incision, releasing incisions, flap elevation, or graft placement.⁴⁻¹³ In contrast, this article reports on a novel vestibular surgical technique: the pinhole surgical technique (PST). The purposes of this study were to examine the predictability and effectiveness of PST and to assess its effect on patient-based outcomes.

Method and materials

In a practice-based retrospective study covering a period of 33 months, 43 patients (16 men, 27 women) between the ages of 31 and 84 years (mean, 57 ± 14.2 years) with gingival recessions on 121 teeth (71 maxillary, 50 mandibular) were treated consecutively and exclusively with PST in the random order they presented themselves. The mean follow-up assessment period was 18 ± 6.7 months (range, 5 to 33 months). All cases were accounted for, with no patient lost to follow-up. Miller Class I and II sites numbered 85; there were 36 Class III sites. Of the total 121 teeth treated, 98 presented baseline recession measurements ≥ 3.0 mm. For each patient, a mean of 2.81 recession sites were treated per surgical appointment. It was the routine and preferred practice of the implementation of PST to treat not one but multiple sites, when present, all at one time (range, 3 to 10 sites).

Inclusion criteria for this retrospective study were as follows: American Society of Anesthesiologists Physical Status I or II¹⁴ and no contraindications for periodontal surgery; presence of maxillary or mandibular single or multiple buccal recessions classified as Class I, II, III, or a combination thereof; absence or presence of restorations or crowns and an identifiable cemento-enamel junction (CEJ); absence of previous periodontal surgical treatment at the involved sites; history of compliance with oral hygiene instructions and periodontal recall;

absence of plaque and bleeding on probing at the surgical sites; and no history of smoking in the 5 years prior to treatment.

Clinical parameters

Preoperatively at the surgical appointment, at the third month, and every 3 or 6 months thereafter depending on patients' needs for periodic checkups, the following four parameters were measured: (1) recession depth (RD), the distance from the marginal gingiva at the midbuccal aspect of the root to the CEJ or coronal margin of the restoration; (2) probing sulcus depth (PD); (3) clinical attachment level (CAL), the sum of RD and PD; and (4) keratinized gingiva (KG), the height of the keratinized gingiva or distance from the marginal gingiva to the mucogingival junction. Additionally, the quality of color and tissue match was assessed by the clinician at all follow-up appointments. Clinical data regarding color and tissue match and photographs taken at each follow-up session were compared to those obtained preoperatively for the purpose of assessing tissue changes and rate of healing. Initial and follow-up RD, as observed on study casts, were measured independent of clinically procured RD data to verify accuracy of clinical measurements.

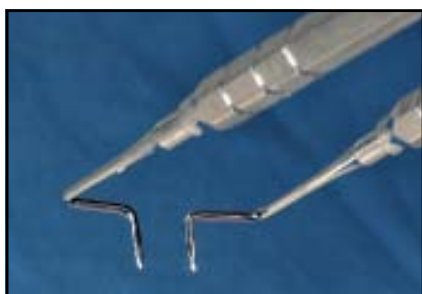

Fig 1 *Trans-Mucosal Papilla Elevators.*

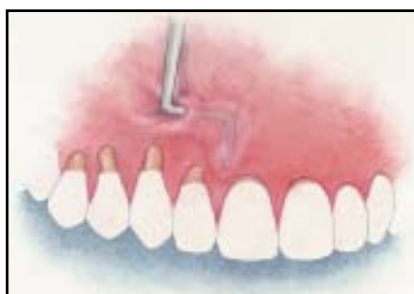


Fig 2 *Full-thickness flap elevation.*

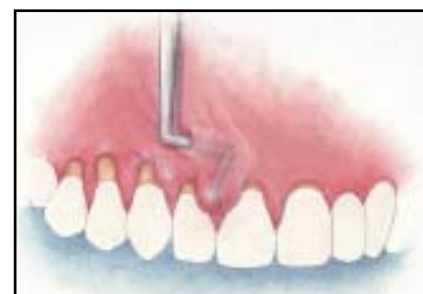
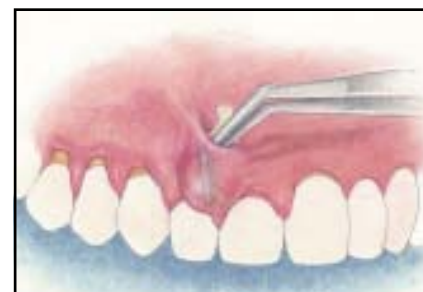
Fig 3 *Elevation of the papillae on each side of the affected tooth.*



Fig 4 (left) *PST graft pliers.*

Fig 5 (right) *Placement of the BM graft material.*



Surgical method

All surgeries were performed by the author. Following injection of local anesthetic, caries, restorations, surface irregularities, and convexities on the root were removed and planed using rotary burs, ultrasonic instruments, and hand curettes. Using a no. 12 scalpel (Bard-Parker), a minimal horizontal incision of 2 to 3 mm was made in the alveolar mucosa near the base of the vestibule, apical to the recipient site(s). In cases with mandibular premolar involvement, the incision was made near the base of the vestibule sufficiently mesial to the root of the first premolar such that, in the judgment

of the clinician, the incision posed no risk of injury to the mental nerve. Specially designed instruments (Trans-Mucosal Papillae Elevators [TMPEs], H & H) were inserted through the entry incision to elevate a full-thickness flap (Figs 1 and 2). Elevation of the flap was guided by visualization of the shape and movement of the instruments through the mucosa and gingival tissue. The flap was then extended coronally and horizontally to allow for elevation of the two adjacent papillae on each side of the denuded root(s) (Fig 3). The inclusion of at least four papillae is a unique feature of PST. This interproximal extension of the flap resulted in a freely movable flap,

which was then positioned coronally to extend beyond the CEJ. For stabilization of the flap, a malleable bioresorbable membrane (BM; Bio-Gide, Geistlich) was used for 100 root defects, while acellular dermal matrix (ADM; Alloderm, BioHorizons) was used for the other 21. Two to four 2 × 12-mm strips of BM presoaked in sterile water were threaded one by one through the entry incision using PST graft pliers (H & H) and tucked into the subgingival spaces under the papillae and marginal soft tissue (Figs 4 and 5). The actual number of strips used depended on the amount of material needed to secure the flap in the desired position.

Tissue tension created by distention or "pouching" of the flap was sufficient in all cases to hold the graft strips in place without sutures, surgical dressing, or tissue adhesive. Gentle digital pressure was applied to the flap for approximately 5 minutes. The entry incision was left to heal by first intention, without suturing.

ADM was used in 21 sites. The slippery nature of ADM required a novel sling suturing technique. A 2 × 5-mm strip of ADM was tied at each end with a separate 4-0, 24-mm, 3/8c bioresorbable suture (Vicryl, Ethicon). Each needle was threaded through the entry incision to emerge from under the facial marginal gingiva of the recipient root. One needle was then threaded under the mesial contact and the other under the distal. The ends of the graft were allowed to slip through the entry incision by tugging on one end and then the other from the oral aspect. Tugging both sutures simultaneously advanced the entire graft strip along with the overlying flap coronally enough to cover the CEJ. Threading each suture under the opposite contacts allowed the sutures to be tightened and knotted from the facial aspect. This manner of suturing stabilized the flap. Loose ends of the bioresorbable sutures were cut and removed when they appeared during follow-up appointments (Figs 6a to 6f).

Postoperative instructions included use of a chlorhexidine gluconate 0.12% oral rinse (Peridex, 3M ESPE) and avoidance of brushing at the surgical site for 6 weeks. Each

patient was assessed for expected clinical signs of early healing the next business day and the following week. Patients were further checked at 3 and 6 weeks. Light debridement was done at each follow-up appointment as necessary. At the sixth week, patients were instructed on the roll brushing technique using an extra-soft toothbrush. Thereafter, patients were re-assessed at every periodontal maintenance appointment, which was generally every 3 months.

Questionnaire and information collection

Using a questionnaire, a staff member interviewed each patient regarding the following patient-based outcome variables. The first variable was esthetics, described by Zucchelli and De Sanctis as a "completely satisfying result for the patient."¹⁵ Each patient was asked to rate his or her degree of esthetic satisfaction on the basis of any set of criteria personal to the patient, expressed as a percentage (0% [total dissatisfaction] to 100% [complete satisfaction]). To add a time-to-event measurement, the patient was further asked to state the time (day) the esthetic improvement (or lack of) was first noticed. Each patient also was asked to rate complications related to pain, bleeding, and swelling on a scale from 0 to 10.¹³ A complication, whether it was pain, bleeding, or swelling, was rated as none to mild if the score was 0 to 3, moderate if the score was

4 to 6, and severe if the score was 7 to 10.¹³ Dentinal sensitivity was rated by the patient on a scale of 0 to 10 according to the effect of hot/cold food and drink, air, toothbrushing, and sweet and sour food on the teeth.¹⁶ Each patient also was asked to rate overall satisfaction with the root coverage procedure as a percentage (0% [totally unsatisfied] to 100% [complete satisfaction]).

Statistical analysis

Quantitative data were recorded as means ± standard deviations. Data were analyzed using the Student *t* test for paired observations to assess changes obtained within and between groups. Kurtosis and skewness curves were used to verify the normality of the data. The significance level for rejection of the null hypotheses for all tests was set at $\alpha = .05$.

Results

Predictability was measured as the percentage of the time duration either complete root coverage or near complete ($\geq 90\%$) root coverage was achieved.¹⁴ Of the 121 sites, 85 were Miller Class I and II and 36 were Miller Class III. When Class III sites were included with data from Class I and II sites, complete root coverage was achieved in 69.4% of sites and 90% defect coverage was obtained in 77.7% of sites. When only the 85 Class I and II sites were computed, complete

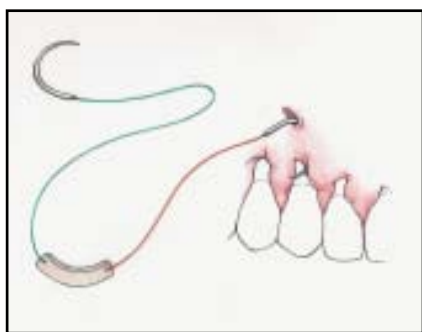


Fig 6a Needle is threaded through the entry incision to emerge under the facial marginal gingiva of the recipient root.

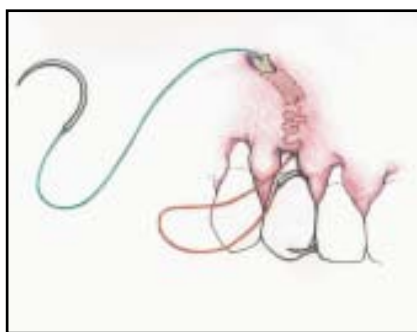


Fig 6b Needle is threaded under the mesial contact.

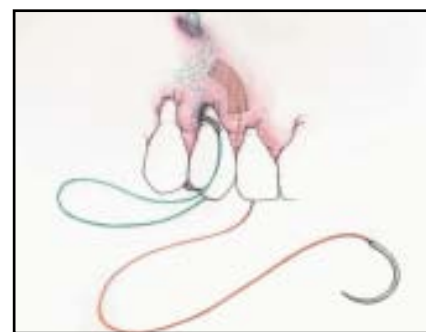


Fig 6c A needle at the other end of the graft has been passed under the flap and under the distal contact to appear at the oral aspect. Tugging on one end and then the other from the facial aspect allowed the ends of the graft to slip through the entry incision.

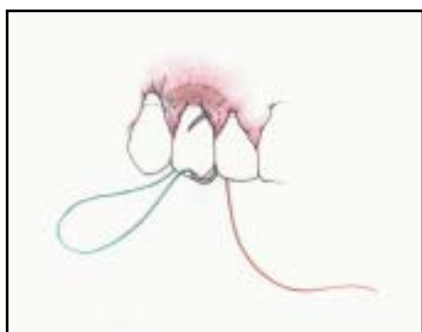


Fig 6d The distal needle is passed under the mesial contact to appear at the facial aspect.

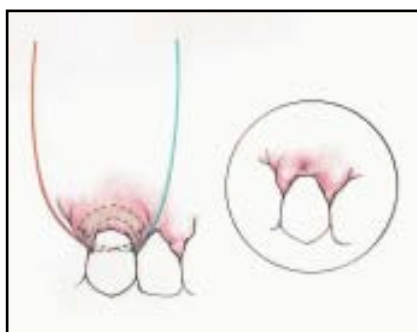

Fig 6e Tugging both sutures from the facial aspect simultaneously advances the entire graft strip coronally. Sutures are tied and the knot is tugged under the flap.

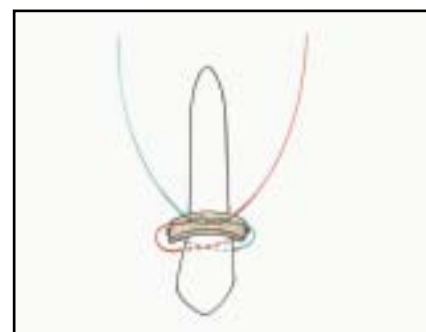


Fig 6f The suturing technique from the facial perspective.

defect coverage was attained in 81.2% of sites and near complete defect coverage was observed in 90.6% of sites.

Effectiveness was measured as the mean percent defect coverage and mean defect reduction.¹⁴ Mean baseline recession for all sites was 3.4 ± 1.0 mm. When all 121 sites were computed, the mean percent defect cover-

age and mean defect reduction were 88.4% and 3.0 ± 1.1 mm, respectively. When only Class I and II sites were included in the calculation, mean percent defect coverage and mean defect reduction were 94% and 3.1 ± 1.1 mm, respectively (Table 1). The mean postoperative measurements of the other relevant parameters for all 121 sites were positive: PD reduc-

tion, 1.4 mm; CAL gain, 4.4 mm; and KT gain, 1.3 mm (Table 1).

The mean number of recession sites treated per procedure was 2.8. The mean follow-up assessment period was 18 ± 6.7 months (range, 5 to 33 months) (Table 1). In a subset of 10 patients with 20 root recession sites, the mean duration of the PST procedure per recession site was 22.3 ± 10.1 minutes.

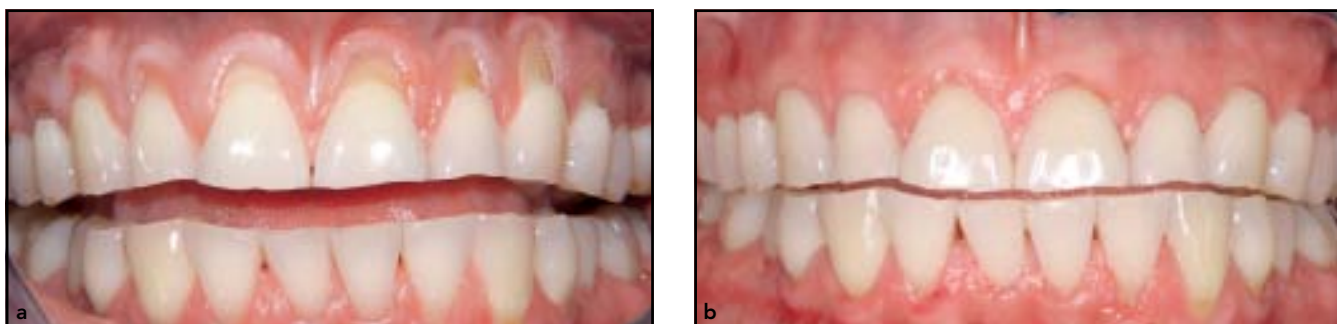
Table 1 Clinical parameters (mean ± SD)			
Parameters	All sites	Class I and II	Class III
No. of sites	121	85	36
Assessment period (mo)	18 ± 6.7	20 ± 6.7	15 ± 5.2
Baseline recession (mm)	3.4 ± 1.0	3.3 ± 1.0	3.6 ± 1.1
Follow-up recession (mm)	0.4 ± 0.8	0.2 ± 0.5	0.9 ± 1.0
Defect coverage (mm)	3.0 ± 1.1	3.1 ± 1.1	2.7 ± 0.9
% defect coverage	88.4 ± 19.8	94.0 ± 14.8	75.5 ± 24.0
No. of sites with complete root coverage	84	69	15
% complete root coverage	69.4	81.2	41.7
% root coverage ≥ 90%	77.7	90.6	47.2
Baseline PD (mm)	2.6 ± 0.7	2.6 ± 0.6	2.4 ± 0.9
Follow-up PD (mm)	1.2 ± 0.4	1.2 ± 0.4	1.3 ± 0.5
PD reduction (mm)	1.4 ± 0.8	1.5 ± 0.7	1.1 ± 0.9
Baseline CAL (mm)	6.0 ± 1.3	5.9 ± 1.2	6.0 ± 1.6
Follow-up CAL (mm)	1.6 ± 0.9	1.4 ± 0.6	2.2 ± 1.1
CAL gain (mm)	4.4 ± 1.4	4.6 ± 1.3	3.8 ± 1.5
Baseline KT (mm)	0.8 ± 1.6	1.1 ± 1.8	0.0 ± 0.0
Follow-up KT (mm)	3.0 ± 1.1	3.3 ± 0.8	2.5 ± 1.3
KT gain (mm)	1.3 ± 1.9	1.2 ± 2.0	1.5 ± 1.7

SD = standard deviation; PD = probing depth; CAL = clinical attachment level; KG = keratinized gingiva.

Regarding patient-based outcomes, the results of the patient questionnaire showed that the mean patient esthetic satisfaction was $94.9\% \pm 1.0\%$. Examples of preoperative and follow-up photographs are shown in Figs 7a and 7b. Furthermore, this esthetic result was observed by patients within a mean of 7.4 ± 13.5 days. The mean overall patient satisfaction over the course of the study was $95.1\% \pm 1.2\%$.

Table 2 further summarizes the levels and durations of symptoms of pain, swelling, and bleeding.

Twenty-five patients reported root sensitivity prior to surgery. Of those 25 patients, 12 (48%) reported sensitivity after surgery. No other adverse events or complications in addition to these symptoms were observed.



Figs 7a and 7b Single surgery on multiple sites with ADM. (a) Presurgical photograph; (b) follow-up 3 years later.

Table 2 Patient-based outcomes	
Pain	
Intensity (degree \pm SD)	0.8 \pm 0.8
No pain (%)	6 (14.0)
Mild pain (%)	32 (74.4)
Moderate pain (%)	3 (7.0)
Severe pain (%)	2 (4.6)
Duration (day \pm SD)	2.6 \pm 1.5
Bleeding	
Intensity (degree \pm SD)	0.7 \pm 0.5
No bleeding (%)	14 (32.6)
Mild bleeding (%)	29 (67.4)
Moderate bleeding (%)	0 (0.0)
Severe bleeding (%)	0 (0.0)
Duration (day \pm SD)	1.2 \pm 1.1
Swelling	
Intensity (degree \pm SD)	0.8 \pm 0.5
No swelling (%)	11 (25.6)
Mild swelling (%)	30 (69.8)
Moderate swelling (%)	2 (4.6)
Severe swelling (%)	0 (0.0)
Duration (day \pm SD)	2.0 \pm 1.8

SD = standard deviation.

Clinical notes and photographs showed healing to be uneventful in all cases. Complete healing for all cases was observed to have taken place at the 6-week follow-up visit. Furthermore, clinical data and follow-up photographs indicated no observable differences in color and tissue match between pre- and postoperative gingival tissue in all cases at the first 3-month follow-up visit and all other follow-up visits thereafter (Fig 7b).

Mean percent defect coverage derived from measuring initial and follow-up recession on study casts (86.5%) was compared to that obtained from intraoral measurements (87.9%). Since there was no significant difference between the two, the clinical data with respect to recession were further confirmed.

Discussion

The most critical factor of root coverage procedures is the technique's predictability,¹⁷ as measured by the frequency of complete root coverage or, alternatively, near complete ($\geq 90\%$) root coverage.¹⁴ Furthermore, complete root coverage has been deemed a primary outcome variable and is considered to be the best indicator of success.^{2,14,18-20} Previous studies on FCTGs have reported the frequency of complete root coverage to vary from 29% to 90%.²⁰⁻²⁶ More recently, Rossberg et al reported that complete root coverage was achieved in 82% of sites in a long-term retrospective study using subepithelial connec-

tive tissue grafts.²⁷ In this study, complete root coverage for Class I and II sites was achieved 81.2% of the time (see Table 1).

With respect to using near complete ($\geq 90\%$) root coverage as an indicator for success, Greenwell et al proposed that for a technique to be deemed successful, 90% (defect) coverage should be achieved at least 75% of the time.¹² In this study, near complete coverage was achieved 90.6% of the time for Class I and II sites and in 77.7% of all sites, of which 29.7% were Class III (see Table 1).

While predictability is measured by frequency of defect coverage, effectiveness is measured by mean percent defect coverage.¹⁴ The criterion for successful mean defect coverage is 80% to 100%.¹² Using PST, mean percent defect coverage for Class I and II sites was 94%. These results compare well with a 6-month case series study by Chambrone and Chambrone²⁸ that evaluated the results obtained with a connective tissue graft placed under a coronally advanced flap for the treatment of multiple gingival recessions involving 28 patients with Class I and II defects. The mean defect coverage for that study was 96%, which was not significantly different from the results with PST.

Regarding the other clinical parameters observed in this study, overall PD reduction (1.4 mm), gain in KG (1.3 mm), and gain in CAL (4.4 mm) showed relatively positive results compared to the results of a study by Paolantonio et al in which these postoperative

clinical parameters of FCTG procedures were reported to be 0.20, 1.93, and 4.40 mm, respectively.²⁹

Patient-based outcomes such as esthetic satisfaction, intensity and duration of postoperative pain, bleeding, reduction in sensitivity, and overall satisfaction are important and relevant considerations in root coverage procedures.^{2,3,20} As has been proposed, the predominant indication for root coverage is esthetic concerns.^{21,28} The results of this study showed that the mean level of esthetic satisfaction was 95.1% through the course of the assessment period of 18 ± 6.7 months (range, 5 to 33 months). Most notably, this result was first observed by patients within a mean of 7.4 days. Although clinical data and photographic records indicated the presence of at least some mild degree of inflammation at the 1-week follow-up appointment, it is notable that most patients observed the degree of improvement to be sufficient to meet their esthetic expectations in fewer than 8 days.

Regarding postoperative pain, PST results were compared to those of a study by Wessel and Tatakis,³⁰ who reported patient outcomes for 23 patients who had undergone procedures with FCTGs or free gingival grafts. Wessel and Tatakis used a visual analog scale (VAS) that scored postoperative pain from 0 to 10, with 0 indicating no pain and 10 indicating severe pain. While mean duration of pain for PST patients was 2.6 ± 1.5 days, with no patient reporting any pain at the end of 1 week, 6 of 12 FCTG

Table 3 Intragroup comparisons

	No. of teeth	Baseline recession (mm ± SD)	Follow-up recession (mm ± SD)	Defect coverage (mm ± SD)	% defect coverage
Maxilla	71	3.4 ± 1.0	0.2 ± 0.5	3.2 ± 1.1	93.6
Mandible	50	3.3 ± 1.0	0.7 ± 1.0	2.7 ± 10.9	79.4
Cariou/restored	45	3.5 ± 0.9	0.6 ± 0.9	2.9 ± 1.0	83.2
Intact roots	76	3.3 ± 1.1	0.3 ± 0.7	3.0 ± 1.1	91.5
Age < 57.5 y	62	3.4 ± 1.1	0.3 ± 0.6	3.1 ± 1.2	90.1
Age > 57.5 y	59	3.3 ± 1.0	0.5 ± 0.9	2.8 ± 0.9	85.4
Early group	53	3.3 ± 1.1	0.1 ± 0.2	3.2 ± 1.1	96.0
Later group	68	3.5 ± 1.0	0.6 ± 0.9	2.9 ± 1.0	83.1
ADM	21	3.6 ± 1.1	0.3 ± 0.8	3.0 ± 1.3	91.4
BM	100	3.4 ± 1.0	0.4 ± 0.8	2.9 ± 1.0	86.9

ADM = acellular dermal matrix; BM = bioresorbable membrane.

patients in the Wessel and Tatakis study reported pain at the end of the third week.³⁰ The mean pain score for PST patients based on the VAS scale was 0.8 ± 0.08 . The mean VAS score for pain for FCTG patients in the Wessel and Tatakis study was 1.6 ± 2.3 . When comparing PST patients with FCTG patients in the Wessel and Tatakis study with respect to postoperative pain pills taken, the number of postsurgery analgesics taken by PST patients was 1.7 ± 2.6 (over-the-counter), while that of Wessel and Tatakis was 8.6 ± 5.5 (ibuprofen

600 mg). Bleeding and swelling for PST patients were mild and of short duration (see Table 2). The relatively rapid diminishment of symptoms in PST patients is coincidental with the quickness of healing observed clinically and in postoperative photographs.

Twenty-five patients in this study reported sensitivity prior to surgery. Of those, 12 (48%) reported sensitivity after surgery. In a study by Pini Prato et al, 4 of 10 (40%) patients with preoperative dentinal sensitivity continued to experience sensitivity postoperatively.³¹

Table 3 compares PST intragroup differences. A slight but significant statistical difference was noted between maxillary and mandibular teeth in terms of follow-up recession (0.2 ± 0.5 and 0.7 ± 1.0 mm, respectively). Significant statistical differences in FCTG results between mandibular and maxillary teeth were also found by Chambrone and Chambrone.²⁸ In the latter study, an FCTG procedure involving multiple sites was performed for 28 patients, half of whom were treated for mandibular recessions while the other half were treated for multiple

maxillary recessions. All sites were either Class I or II. Mean final recession depths for mandibular and maxillary groups were 0.21 and 0.07 mm, respectively, a threefold difference. Interestingly, results with PST also showed an approximate threefold difference between the mandibular and maxillary procedures (0.7 and 0.2 mm, respectively). The greater final RD in the PST study as compared to that of Chambrone and Chambrone²⁸ may be due to the inclusion of Class III sites in the PST study. PST Class III defects accounted for 16 of 50 mandibular sites and 20 of 71 maxillary sites. Chambrone and Chambrone cited depth of the vestibular fornix, flap tension, flap thickness, and mucogingival phenotype as possible proximal links to explain their findings.²⁸ This difference between mandibular and maxillary groups may also be a result of the possibility that functional mechanical forces act much more heavily on wound margins in the mandible than in the maxilla, as suggested by Amarante et al.³² It should also be noted that even though Class III cases were included, 79.4% defect coverage for all mandibular PST procedures still measured favorably against the criterion for successful mean defect coverage suggested by Greenwell et al, which was 80% to 100%.¹² Further investigations focusing on the effects of PST or FCTGs in mandibular sites are recommended.

With respect to nonintact roots, results with PST were concordant with those of a previous study by

Goldstein et al,³³ which concluded that coverage of previously carious or restored roots is just as predictable as coverage of intact roots.

In PST cases, no significant differences in treatment results were evident between younger and older age groups.

With regard to the surgeon's learning curve as a possible factor for bias,¹⁸ comparing the results of an earlier group with those of a later group categorized according to the time of surgery yielded percent defect coverage results of 96.0% and 83.1%, respectively. Since defect coverage for the early group was slightly higher, though not statistically significantly better than that of the later group, effect of the surgeon's learning curve or progressive improvement as a possible avenue of bias was not apparent (see Table 3). In addition, with respect to comparing results between BM and ADM, no significant differences emerged (see Table 3).

Aside from the intragroup results reported in Table 3, this study also addressed the issue of selection bias¹⁸ of the treated sites. During the observation period, all patients needing root coverage surgery were offered PST along with FCTG procedures, but all patients preferred the PST and were treated as they wished. Thus, patients being treated consecutively with the same procedure (PST) in the random order they presented themselves addressed the issue of selection bias to the extent possible in this retrospective study.

Results indicate that with PST, multiple sites (see Fig 7a) may be treated simultaneously in significantly less time and therefore may incur lesser costs. Recession sites treated (procedures) per appointment for this study and the study by Griffin et al¹³ were 2.8 and 1.45, respectively.

According to Griffin et al,¹³ the most significant risk indicator for postoperative pain was time duration of the procedure, particularly for those who received autogenous grafts. The difference in mean duration of surgery per recession site (procedure) between this study and the study by Griffin et al¹³ was substantial and significant: 22.3 ± 10.1 (range, 18 to 40) and 45.1 ± 19.1 minutes, respectively.

Thus, it is reasonable to conclude that within the limits of this study, PST may be deemed a predictable, effective, minimally invasive, and time- and cost-effective alternative to FCTG techniques for obtaining optimal patient-based outcomes. In light of the potential impact of PST on patient benefits, further investigation through randomized controlled trials to prove its plausibility is warranted.

Disclosure

Dr Chao has a patent (no. 8,007,278) for TMPE instruments and a trademark registered for Pinhole and PST.

References

1. Miller PD Jr. Regenerative and reconstructive periodontal plastic surgery. Mucogingival surgery. *Dent Clin North Am* 1988; 32:287–306.
2. Rocuzzo M, Bunino M, Needleman I, Sanz M. Periodontal plastic surgery for treatment of localized recessions: A systematic review. *J Clin Periodontol* 2002; 29:178–194.
3. Oates TW, Robinson M, Gunsolley JC. Surgical therapies for the treatment of gingival recession. A systematic review. *Ann Periodontol* 2003;8:303–320.
4. Consensus report. Mucogingival therapy. *Ann Periodontol* 1996;1:702–706.
5. Miller PD Jr. Root coverage using a free soft tissue autograft following citric acid application. II. Treatment of the carious root. *Int J Periodontics Restorative Dent* 1983;3(5):39–51.
6. Cairo F, Pagliaro U, Nieri M. Treatment of gingival recession with coronally advanced flap procedures: A systematic review. *J Clin Periodontol* 2008;35(suppl): 136–162.
7. Tarnow DP. Semilunar coronally repositioned flap. *J Clin Periodontol* 1986;13: 182–185.
8. Harris RJ. Connective tissue grafts combined with either double pedicle grafts or coronally positioned pedicle grafts: Results of 266 consecutively treated defects in 200 patients. *Int J Periodontics Restorative Dent* 2002;22:463–471.
9. Kimble KM, Eber RM, Soehren S, Shyr Y, Wang HL. Treatment of gingival recession using a collagen membrane with or without the use of demineralized freeze-dried bone allograft for space maintenance. *J Periodontol* 2004;75:210–220.
10. Pilloni A, Paolantonio M, Camargo PM. Root coverage with a coronally positioned flap used in combination with enamel matrix derivative: 18-month clinical evaluation. *J Periodontol* 2006;77:2031–2039.
11. Moses O, Artzi Z, Sculean A, et al. Comparative study of two root coverage procedures: A 24-month follow-up multicenter study. *J Periodontol* 2006;77: 195–202.
12. Greenwell H, Bissada NF, Henderson RD, Dodge JR. The deceptive nature of root coverage results. *J Periodontol* 2000;71: 1327–1337.
13. Griffin TJ, Cheung WS, Zavras AI, Damoulis PD. Postoperative complications following gingival augmentation procedures. *J Periodontol* 2006;77:2070–2079.
14. Maloney WJ, Weinberg MA. Implementation of the American Society of Anesthesiologists Physical Status classification system in periodontal practice. *J Periodontol* 2008;79:1124–1126.
15. Zucchelli G, De Sanctis M. Treatment of multiple recession-type defects in patients with esthetic demands. *J Periodontol* 2000;71:1506–1514.
16. Pereira R, Chava VK. Efficacy of a 3% potassium nitrate desensitizing mouthwash in the treatment of dentinal hypersensitivity. *J Periodontol* 2001;72:1720–1725.
17. Greenwell H, Fiorellini J, Giannobile W, et al. Oral reconstructive and corrective considerations in periodontal therapy. *J Periodontol* 2005;76:1588–1600.
18. Clauser C, Nieri M, Franceschi D, Pagliaro U, Pini-Prato G. Evidence-based mucogingival therapy. Part 2: Ordinary and individual patient data meta-analyses of surgical treatment of recession using complete root coverage as the outcome variable. *J Periodontol* 2003;74:741–756.
19. Rotundo R, Nieri M, Mori M, Clauser C, Prato GP. Aesthetic perception after root coverage procedure. *J Clin Periodontol* 2008;35:705–712.
20. Pagliaro U, Nieri M, Franceschi D, Clauser C, Pini-Prato G. Evidence-based mucogingival therapy. Part I: A critical review of the literature on root coverage procedures. *J Periodontol* 2003;74:709–740.
21. Miller PD Jr. Root coverage using the free soft tissue autograft citric acid application. III. A successful and predictable procedure in areas of deep-wide recession. *Int J Periodontics Restorative Dent* 1985; 5(2):15–37.
22. Holbrook T, Ochsenbein C. Complete coverage of the denuded root surface with a one-stage gingival graft. *Int J Periodontics Restorative Dent* 1983;3(3):8–27.
23. Nelson S. The subpedicle connective tissue graft, A bilaminar reconstructive procedure for the coverage of denuded root surfaces. *J Periodontol* 1987;58:95–102.
24. Borghetti A, Gardella JP. Thick gingival autograft for the coverage of gingival recession: A clinical evaluation. *Int J Periodontics Restorative Dent* 1990;10: 216–229.
25. Tolmie PN, Rubins RP, Buck GS, Vagianos V, Lanz JC. The predictability of root coverage by way of free gingival autografts and citric acid application: An evaluation by multiple clinicians. *Int J Periodontics Restorative Dent* 1991;11:261–271.
26. Harris RJ. Root coverage with connective tissue grafts: An evaluation of short- and long-term results. *J Periodontol* 2002;73: 1054–1059.
27. Rossberg M, Eickholz P, Raetzke P, Ratka-Krüger P. Long-term results of root coverage with connective tissue in the envelope technique: A report of 20 cases. *Int J Periodontics Restorative Dent* 2008; 28:19–27.
28. Chambrone LA, Chambrone L. Subepithelial connective tissue grafts in the treatment of multiple recession-type defects. *J Periodontol* 2006;77:909–916.
29. Paolantonio M, Dolci M, Esposito P, et al. Subpedicle acellular dermal matrix graft and autogenous connective tissue graft in the treatment of gingival recessions: A comparative 1-year clinical study. *J Periodontol* 2002;73:1299–1307.
30. Wessel JR, Tatakis DN. Patient outcomes following subepithelial connective tissue graft and free gingival graft procedures. *J Periodontol* 2008;79:425–430.
31. Pini-Prato G, Pagliaro U, Baldi C, et al. Coronally advanced flap procedure for root coverage. Flap with tension versus flap without tension: A randomized controlled clinical study. *J Periodontol* 2000; 71:188–201.
32. Amarante SA, Leknes KN, Skavland J, Lie T. Coronally positioned flap procedures with or without a bioabsorbable membrane in the treatment of human gingival recession. *J Periodontol* 2000;71: 989–998.
33. Goldstein M, Nasatzky E, Goultschin J, Boyan BD, Schwartz Z. Coverage of previously carious roots is as predictable a procedure as coverage of intact roots. *J Periodontol* 2002;73:1419–1426.